

Clinical Viewpoint

Why Your Patient May Need a Bankart Repair Plus Remplissage

Amit M. Momaya, MD, Joshua P. Broussard, Elizabeth Powell, MD

<https://doi.org/10.26603/001c.158195>

International Journal of Sports Physical Therapy

Vol. 21, Issue 3, 2026

Anterior shoulder instability, especially in contact athletes, is a relatively common sports pathology. Despite refinements in arthroscopic Bankart repair (ABR), recurrent instability and reoperation remain concerns in younger overhead and contact athletes. Remplissage has gained popularity through the years when used in conjunction with ABR. Adding remplissage to arthroscopic Bankart repair may lower the risk of recurrent instability. The purpose of this clinical commentary is to provide an evidence-based overview of arthroscopic Bankart repair with remplissage, including technique, biomechanics, outcomes, and indications.

INTRODUCTION

Glenohumeral (shoulder) dislocations are relatively common in the United States, with over 77,000 occurring each year.¹ The vast majority of cases are anterior dislocations (95%).^{2,3} Bankart lesions are frequently present in these anterior dislocations. For cases with minimal glenoid bone loss, arthroscopic Bankart repair (ABR) remains a widely used procedure for shoulder stabilization.⁴⁻⁶

Despite advancements to the procedure, high failure rates leading to recurrent shoulder instability remain a concern in patients returning to collision sports (e.g., rugby, ice hockey, American football).⁶⁻¹⁰ Current literature reports widely variable ABR failure rates, ranging from approximately 3 to 55% in athletes.¹¹⁻¹³ While ABR stabilizes the shoulder, it can fail to address the underlying bone lesions that can promote further instability and delay return to sport in young, athletic patients. Evidence has shown that failure is often driven by morphology due to bone loss on the glenoid and humeral head.^{14,15}

These insights have drawn attention to managing humeral-sided defects that lead to instability. A Hill-Sachs lesion is a compression defect on the humeral head that forms after it comes into contact with the anterior glenoid rim following a shoulder dislocation.¹⁶ To address these types of bony defects, remplissage with ABR may help better stabilize the joint, lowering recurrent instability while maintaining a similar range of motion (ROM) compared with isolated ABR.¹⁷ The purpose of this clinical commentary is to provide an evidence-based overview of arthroscopic Bankart repair with remplissage, including technique, biomechanics, clinical outcomes, and indications.

TECHNIQUE

Remplissage entails filling the Hill-Sachs lesion, a posterolateral humeral head defect ([Figure 1A, B](#)), using an infraspinatus tenodesis and posterior capsulodesis for joint stabilization to prevent anterior shoulder instability.¹⁸ One

method for performing a remplissage uses anchors placed into the Hill-Sachs defect ([Figure 1C](#)). This procedure involves standard arthroscopic Bankart preparation using anterior portals, preparation of the Hill-Sachs defect via a posterior working portal, and placement of one or two anchors in the defect. Sutures are passed through the infraspinatus tendon and posterior capsule and then tensioned to compress the tendon and capsule into the lesion ([Figure 2](#)). This effectively converts the lesion from intra-articular to extra-articular, preventing engagement of the anterior glenoid rim with the Hill-Sachs defect.^{16,18,19} It also serves as a check rein for the humeral head from sliding too anteriorly. [Figure 2](#) shows arthroscopic pictures of a remplissage procedure performed in a patient.

BIOMECHANICS OF REMPLISSAGE

Biomechanically, adding remplissage to Bankart repair aims to prevent Hill-Sachs engagement in the apprehension position (abduction-external rotation), restore normal shoulder stability, and reduce end-range laxity that predisposes patients to an anterior shoulder dislocation.^{20,21} Engagement refers to the Hill-Sachs lesion catching or locking onto the anterior glenoid rim, which can lever the humeral head anterior to the glenoid risking subluxation or dislocation. Cadaveric studies investigating these biomechanical benefits of remplissage generally support its use with ABR in cases where Hill-Sachs lesions are prone to engagement. In a bipolar-bone loss model (combined glenoid and humeral head defects), ABR alone failed to prevent engagement at end-range external rotation, whereas ABR with remplissage restored biomechanical stability in all specimens.²² A similar cadaveric study using models with moderate to large Hill-Sachs defects demonstrated that remplissage consistently prevented engagement, unlike the isolated ABR group.²³ These biomechanical studies support ABR with remplissage as a humeral-side augmentation that consistently neutralizes engagement mechanics and thereby reduces the risk of recurrent instability.

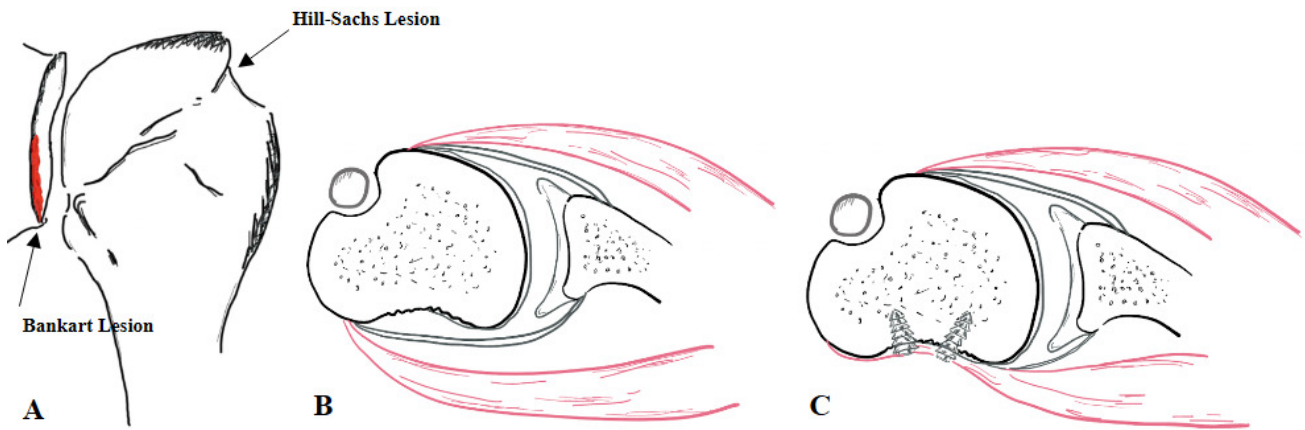


Figure 1. (A) Bankart and Hill-Sachs lesion. (B) Illustration detailing axial views of a Hill-Sachs lesion followed by (C) a remplissage using two anchors to capture the posterior capsule and infraspinatus tendon

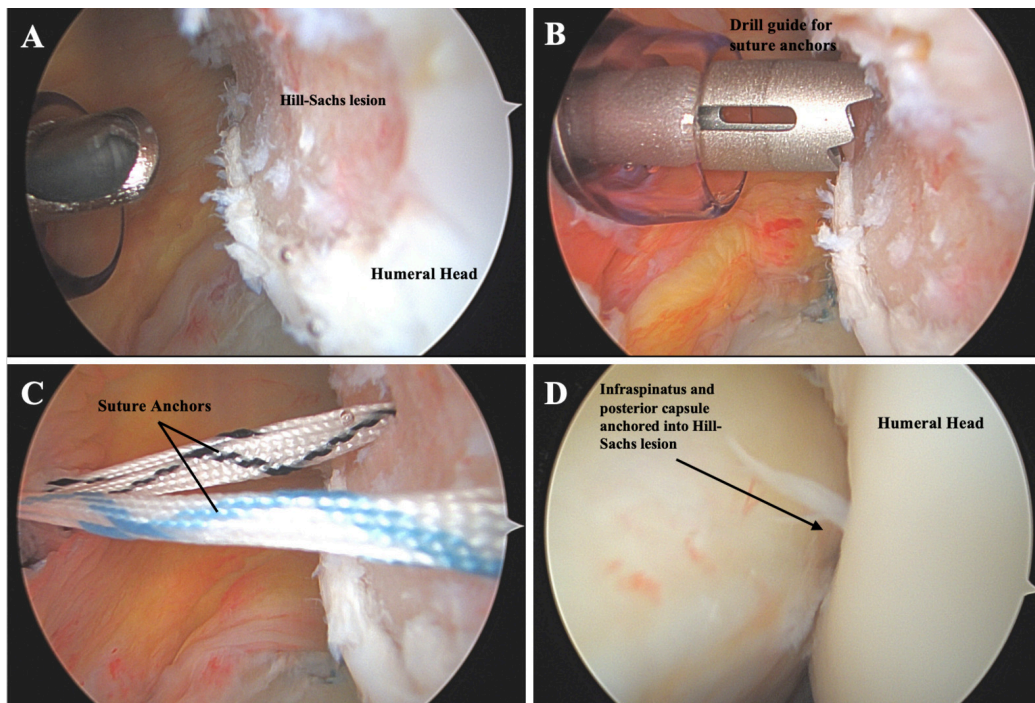


Figure 2. (A) The posterolateral humeral head has a large Hill-Sachs lesion. (B) A guide is placed through the posterior portal cannula in preparation to drill into the defect for anchor placement. (C) Two anchors have been placed in the defect with four sutures exiting total. (D) A portion of the infraspinatus and posterior capsule have been tied down into the Hill-Sachs lesion to complete the remplissage.

CLINICAL OUTCOMES

Clinical evidence supporting remplissage exists across multiple studies. In the largest double-blinded multicenter randomized control trial evaluating remplissage, 108 individuals with minimal glenoid bone loss (<15%) were evenly assigned to ABR alone or ABR plus remplissage. Adding remplissage to ABR reduced redislocation rates at two years (18% ABR vs 4% ABR with remplissage), with no statistical difference in patient-reported outcomes or shoulder function.²⁴ Their medium-term follow-up (≥ 4 years) yielded similar results, with failure (postoperative redislocation

within one year) rates of 22% vs 8%, respectively, and recurrent instability (redislocation or ≥ 2 subluxations >1 year postoperative) rates of 30% vs 10%, respectively.²⁵ Additionally, systematic reviews have also concluded that ABR with remplissage improves return-to-sport rates and reduces recurrent anterior shoulder instability in patients with Hill-Sachs lesions compared to ABR alone.^{13,26}

In a large comparative meta-analysis, recurrent dislocations and revisions were significantly more common in the isolated ABR cohort (n=704) compared to the ABR with remplissage cohort (n=507). Villarreal-Espinosa et al. found higher odds of redislocation (OR = 4.22) and revision (OR

= 3.36) after ABR alone, with no significant differences in ROM compared with the remplissage cohort.²⁷

Athlete-focused data parallels these findings. In a systematic review including 538 athletes, 86% returned to sport after ABR plus remplissage, with higher odds of returning to any level (OR = 2.71) or to a previous or higher level (OR = 2.07) compared with isolated ABR. Moreover, recurrence of shoulder instability with remplissage was 5% in athletes and 7.3% overall, while the risk of reoperation (OR = 0.18) was significantly lower in ABR with remplissage when compared to alternative techniques.¹³

Long-term outcomes appear to remain stable. A systematic review of studies with \geq 5-year outcomes (mean: 9 years) found that ABR with remplissage resulted in an overall 10% recurrent instability rate, 8% redislocation, and 76% return-to-sport rate, while also preserving external rotation.²⁷ Current clinical evidence indicates that adding a remplissage to ABR decreases recurrent instability and reoperations while maintaining shoulder ROM.²⁸

INDICATIONS

Patients at highest risk of failure after isolated ABR include young, contact athletes, patients with bipolar bone loss, and patients with high Instability Severity Index (ISI) scores.^{6,7,29-33} The senior author of this paper (AMM) considers adding remplissage for young high-risk patients and athletes in contact or overhead sports. Common indications for remplissage include engaging Hill-Sachs lesions with subcritical glenoid bone loss (<20%), contact athletes, high ISI scores, and revision after failed primary ABR ([Table 1](#)).^{20,34,35}

Risk stratification tools like ISI aid clinicians in making informed decisions on surgical technique selection. ISI scores correlate with instability recurrence after ABR, with recurrence rising sharply with higher scores (i.e., 15% for ISI 0-3, 41% for ISI 4-6, and 71% for ISI >6), suggesting remplissage for management in high-risk profiles.³⁶ In the setting of revision, remplissage has shown favorable stability and return-to-sport, further supporting its role when prior ABR has failed.²⁶

Table 1. Relative Indications for Adding Remplissage to ABR

Engaging Hill-Sachs lesions
Athletes in contact or collision sports
Multiple dislocations prior to surgery
Revision after Bankart repair failure
High risk of recurrence (young age, hyperlaxity)
Patients with a high ISI score

ISI, Instability Severity Index

REHABILITATION

Historically, one concern of ABR with remplissage was the possible loss of external rotation. Early literature identified conflicting limitations with internal and external ROM during abduction. However, more recent large comparative studies have demonstrated no difference in postoperative external rotation constraints between ABR and remplissage.^{17,37} Athlete and mixed-cohort meta-analyses further support these findings, depicting no clinically meaningful external rotation deficits with remplissage.²⁷ Thus, conventional rehabilitation protocols used for isolated ABR are not typically changed for individuals undergoing ABR with remplissage.³⁸ However, close communication between the surgeon and rehabilitation team should guide recovery based on the patient's intraoperative findings and concomitant procedures for optimal recovery.

CONCLUSION

When paired with ABR, remplissage may reduce the risk of recurrent instability without a clinically meaningful loss of external rotation and may improve return-to-sports-rates compared to isolated ABR in athletes.

Published: March 01, 2026 CST.

© The Author(s)



This is an open-access article distributed under the terms of the Creative Commons Attribution 4.0 International License (CCBY-NC-4.0). View this license's legal deed at <https://creativecommons.org/licenses/by-nc/4.0> and legal code at <https://creativecommons.org/licenses/by-nc/4.0/legalcode> for more information.

REFERENCES

1. Patrick CM, Snowden J, Eckhoff MD, et al. Epidemiology of shoulder dislocations presenting to United States emergency departments: An updated ten-year study. *World J Orthop.* 2023;14(9):690-697. doi:[10.5312/wjo.v14.i9.690](https://doi.org/10.5312/wjo.v14.i9.690)
2. Zacchilli MA, Owens BD. Epidemiology of shoulder dislocations presenting to emergency departments in the United States. *JBJS.* 2010;92(3):542. doi:[10.2106/JBJS.I.00450](https://doi.org/10.2106/JBJS.I.00450)
3. Cutts S, Prempeh M, Drew S. Anterior shoulder dislocation. *Ann R Coll Surg Engl.* 2009;91(1):2-7. doi:[10.1308/003588409X359123](https://doi.org/10.1308/003588409X359123)
4. Hurley ET, Danilkowicz RM, Paul AV, et al. Majority of studies show similar rates of return to play after arthroscopic Bankart repair or Latarjet procedure: A systematic review. *Arthroscopy.* 2024;40(2):515-522. doi:[10.1016/j.arthro.2023.04.017](https://doi.org/10.1016/j.arthro.2023.04.017)
5. Clifford AL, Hurley E, Doyle TR, Dickens JF, Anakwenze OA, Klifto CS. Treatment of anterior shoulder instability: a comprehensive review. *J Hand Surg Glob Online.* 2024;6(5):610-613. doi:[10.1016/j.jhsg.2024.04.013](https://doi.org/10.1016/j.jhsg.2024.04.013)
6. Pasqualini I, Turan OA, Hurley ET, et al. Return to sports following arthroscopic Bankart repair in collision athletes: A systematic review. *Shoulder Elbow.* 2025;17(3):288-297. doi:[10.1177/17585732241249959](https://doi.org/10.1177/17585732241249959)
7. Twomey-Kozak J, Whitlock KG, O'Donnell JA, Anakwenze OA, Klifto CS. Shoulder dislocations among high school-aged and college-aged athletes in the United States: an epidemiologic analysis. *JSES International.* 2021;5(6):967-971. doi:[10.1016/j.jseint.2021.06.006](https://doi.org/10.1016/j.jseint.2021.06.006)
8. Torrance E, Clarke CJ, Monga P, Funk L, Walton MJ. Recurrence after arthroscopic labral repair for traumatic anterior instability in adolescent rugby and contact athletes. *Am J Sports Med.* 2018;46(12):2969-2974. doi:[10.1177/0363546518794673](https://doi.org/10.1177/0363546518794673)
9. Nakagawa S, Mae T, Sato S, Okimura S, Kuroda M. Risk factors for the postoperative recurrence of instability after arthroscopic Bankart repair in athletes. *Orthop J Sports Med.* 2017;5(9):2325967117726494. doi:[10.1177/2325967117726494](https://doi.org/10.1177/2325967117726494)
10. Pasqualini I, Rossi LA, Franco JVA, et al. Results after arthroscopic Bankart repair in contact athletes should not be reported globally because of the high variability in recurrences among the different contact or collision sports: A systematic review. *Arthroscopy.* 2024;40(2):523-539.e2. doi:[10.1016/j.arthro.2023.06.037](https://doi.org/10.1016/j.arthro.2023.06.037)
11. Bessière C, Trojani C, Carles M, Mehta SS, Boileau P. The open Latarjet procedure is more reliable in terms of shoulder stability than arthroscopic Bankart repair. *Clin Orthop Relat Res.* 2014;472(8):2345-2351. doi:[10.1007/s11999-014-3550-9](https://doi.org/10.1007/s11999-014-3550-9)
12. Torrance E, Clarke CJ, Monga P, Funk L, Walton MJ. Recurrence after arthroscopic labral repair for traumatic anterior instability in adolescent rugby and contact athletes. *Am J Sports Med.* 2018;46(12):2969-2974. doi:[10.1177/0363546518794673](https://doi.org/10.1177/0363546518794673)
13. Davis WH, DiPasquale JA, Patel RK, et al. Arthroscopic remplissage combined with Bankart repair results in a higher rate of return to sport in athletes compared with bankart repair alone or the latarjet procedure: A systematic review and meta-analysis. *Am J Sports Med.* 2023;51(12):3304-3312. doi:[10.1177/03635465221138559](https://doi.org/10.1177/03635465221138559)
14. Burkhart SS, De Beer JF. Traumatic glenohumeral bone defects and their relationship to failure of arthroscopic Bankart repairs: significance of the inverted-pear glenoid and the humeral engaging Hill-Sachs lesion. *Arthroscopy.* 2000;16(7):677-694. doi:[10.1053/jars.2000.17715](https://doi.org/10.1053/jars.2000.17715)
15. Yamamoto N, Itoi E, Abe H, et al. Contact between the glenoid and the humeral head in abduction, external rotation, and horizontal extension: A new concept of glenoid track. *J Shoulder Elbow Surg.* 2007;16(5):649-656. doi:[10.1016/j.jse.2006.12.012](https://doi.org/10.1016/j.jse.2006.12.012)
16. Fox JA, Sanchez A, Zajac TJ, Provencher MT. Understanding the Hill-Sachs Lesion in its role in patients with recurrent anterior shoulder instability. *Curr Rev Musculoskelet Med.* 2017;10(4):469-479. doi:[10.1007/s12178-017-9437-0](https://doi.org/10.1007/s12178-017-9437-0)
17. Haroun HK, Sobhy MH, Abdelrahman AA. Arthroscopic Bankart repair with remplissage versus Latarjet procedure for management of engaging Hill-Sachs lesions with subcritical glenoid bone loss in traumatic anterior shoulder instability: a systematic review and meta-analysis. *J Shoulder Elbow Surg.* 2020;29(10):2163-2174. doi:[10.1016/j.jse.2020.04.032](https://doi.org/10.1016/j.jse.2020.04.032)

18. Cecere RA, Williams AB, Gulotta LV. The Remplissage technique as a treatment for shoulder instability. *Arthrosc Tech.* 2025;14(4). doi:[10.1016/j.eats.2024.103292](https://doi.org/10.1016/j.eats.2024.103292)
19. Kim DH, Kim JY, Park J, et al. Combined double-pulley Remplissage and Bankart repair. *Arthrosc Tech.* 2022;11(3):e419-e425. doi:[10.1016/j.eats.2021.11.011](https://doi.org/10.1016/j.eats.2021.11.011)
20. Itoi E. “On-track” and “off-track” shoulder lesions. *EFORT Open Rev.* 2017;2(8):343-351. doi:[10.1302/2058-5241.2.170007](https://doi.org/10.1302/2058-5241.2.170007)
21. Elkinson I, Giles JW, Faber KJ, et al. The effect of the remplissage procedure on shoulder stability and range of motion: an in vitro biomechanical assessment. *J Bone Joint Surg Am.* 2012;94(11):1003-1012. doi:[10.2106/JBJS.J.01956](https://doi.org/10.2106/JBJS.J.01956)
22. Hartzler RU, Bui CNH, Jeong WK, et al. Remplissage of an off-track Hill-Sachs lesion is necessary to restore biomechanical glenohumeral joint stability in a bipolar bone loss model. *Arthroscopy.* 2016;32(12):2466-2476. doi:[10.1016/j.arthro.2016.04.030](https://doi.org/10.1016/j.arthro.2016.04.030)
23. Giles JW, Elkinson I, Ferreira LM, et al. Moderate to large engaging Hill-Sachs defects: an in vitro biomechanical comparison of the remplissage procedure, allograft humeral head reconstruction, and partial resurfacing arthroplasty. *J Shoulder Elbow Surg.* 2012;21(9):1142-1151. doi:[10.1016/j.jse.2011.07.017](https://doi.org/10.1016/j.jse.2011.07.017)
24. MacDonald P, McRae S, Old J, et al. Arthroscopic Bankart repair with and without arthroscopic infraspinatus remplissage in anterior shoulder instability with a Hill-Sachs defect: a randomized controlled trial. *J Shoulder Elbow Surg.* 2021;30(6):1288-1298. doi:[10.1016/j.jse.2020.11.013](https://doi.org/10.1016/j.jse.2020.11.013)
25. Woodmass JM, McRae S, Lapner P, et al. Arthroscopic Bankart repair with Remplissage in anterior shoulder instability results in fewer redislocations than Bankart repair alone at medium-term follow-up of a randomized controlled trial. *Am J Sports Med.* 2024;52(8):2055-2062. doi:[10.1177/03635465241254063](https://doi.org/10.1177/03635465241254063)
26. Gouveia K, Harbour E, Athwal GS, Khan M. Return to sport after arthroscopic Bankart repair with Remplissage: A systematic review. *Arthroscopy.* 2023;39(4):1046-1059.e3. doi:[10.1016/j.arthro.2022.12.032](https://doi.org/10.1016/j.arthro.2022.12.032)
27. Villarreal-Espinosa JB, Kay J, Ramappa AJ. Arthroscopic Bankart with remplissage results in lower rates of recurrent instability with similar range of motion compared to isolated arthroscopic Bankart for anterior glenohumeral instability: A systematic review and meta-analysis. *Knee Surg Sports Traumatol Arthrosc.* 2024;32(2):243-256. doi:[10.1002/ksa.12054](https://doi.org/10.1002/ksa.12054)
28. Tansey PJ, Clark DS, Ruelos VCB, Lindeman RW, Somerson JS. Arthroscopic Bankart repair with remplissage results in low recurrent instability rates without reducing shoulder range of motion at midterm follow-up: A systematic review of studies with minimum 5-year outcomes. *Am J Sports Med.* Published online September 24, 2025;3635465251324930. doi:[10.1177/03635465251324930](https://doi.org/10.1177/03635465251324930)
29. Giacomo GD, Itoi E, Burkhart SS. evolving concept of bipolar bone loss and the Hill-Sachs lesion: From “engaging/non-engaging” lesion to “on-track/off-track” lesion. *Arthroscopy.* 2014;30(1):90-98. doi:[10.1016/j.arthro.2013.10.004](https://doi.org/10.1016/j.arthro.2013.10.004)
30. Bulleit CH, Hurley ET, Jing C, et al. Risk factors for recurrence following arthroscopic Bankart repair: A systematic review. *J Shoulder Elbow Surg.* 2024;33(11):2539-2549. doi:[10.1016/j.jse.2024.04.017](https://doi.org/10.1016/j.jse.2024.04.017)
31. Schwihla I, Wieser K, Grubhofer F, Zimmermann SM. Long-term recurrence rate in anterior shoulder instability after Bankart repair based on the on- and off-track concept. *J Shoulder Elbow Surg.* 2023;32(2):269-275. doi:[10.1016/j.jse.2022.07.025](https://doi.org/10.1016/j.jse.2022.07.025)
32. Balg F, Boileau P. The instability severity index score. A simple pre-operative score to select patients for arthroscopic or open shoulder stabilisation. *J Bone Joint Surg Br.* 2007;89(11):1470-1477. doi:[10.1302/0301-620X.89B11.18962](https://doi.org/10.1302/0301-620X.89B11.18962)
33. Sudah SY, Menendez ME. Classifications in Brief: The instability severity index score for predicting recurrent shoulder instability after arthroscopic Bankart repair. *Clin Orthop Relat Res.* 2023;481(2):382-386. doi:[10.1097/CORR.0000000000002386](https://doi.org/10.1097/CORR.0000000000002386)
34. Dickens JF, Owens BD, Cameron KL, et al. The effect of subcritical bone loss and exposure on recurrent instability after arthroscopic Bankart repair in intercollegiate American football. *Am J Sports Med.* 2017;45(8):1769-1775. doi:[10.1177/0363546517704184](https://doi.org/10.1177/0363546517704184)
35. Shaha JS, Cook JB, Song DJ, et al. Redefining “critical” bone loss in shoulder instability: functional outcomes worsen with “subcritical” bone loss. *Am J Sports Med.* 2015;43(7):1719-1725. doi:[10.1177/0363546515578250](https://doi.org/10.1177/0363546515578250)
36. van Blommestein MYH, Govaert LHM, van der Palen J, et al. Instability severity index score predicts recurrent shoulder instability after arthroscopic Bankart repair. *Knee Surg Sports Traumatol Arthrosc.* 2024;32(8):2152-2160. doi:[10.1002/ksa.12235](https://doi.org/10.1002/ksa.12235)

37. Gonzalez-Morgado D, Ardebol J, Noble MB, Galasso LA, Menendez ME, Denard PJ. No difference in external rotation loss after isolated Bankart repair, Remplissage, or Latarjet: A systematic review and meta-analysis. *Am J Sports Med.* 2025;53(2):493-500. doi:[10.1177/03635465241241825](https://doi.org/10.1177/03635465241241825)

38. Villarreal-Espinosa JB, Reinold MM, Khak M, et al. Rehabilitation protocol variability following arthroscopic Bankart repair and Remplissage for management of anterior shoulder instability: A systematic review. *Int J Sports Phys Ther.* 2024;19(10):1172-1187. doi:[10.26603/001c.123481](https://doi.org/10.26603/001c.123481)